



## PATIENT

Cooper House

## SPECIES

Canine

## BREED

CKCS

## SEX

MN

## AGE

9 y

## WEIGHT

13.95 kg

## INTERPRETED BY

Keith Blass, DVM, MS,  
DACVIM (Cardiology)

## IMAGING PERFORMED BY

Dr. Brian Barnes

## HOSPITAL NAME

Westview VH

## REFERRING VET

Dr. Barnes

## INVOICE

## DATE

11/18/25

## PRESENTING CLINICAL SIGNS

History of stage B2 degenerative valve disease. Receiving pimobendan 5 mg BID. Doing well.

## ECHOCARDIOGRAPHIC FINDINGS

2D, M-mode, and Doppler study.

Left atrial size is normal. The mitral valve leaflets are mildly thickened and exhibit mild systolic prolapse. There is Doppler evidence of mitral regurgitation present. Left ventricular dimensions are normal. Left ventricular systolic function is normal. The aorta and aortic valve are normal. Right atrial and right ventricular dimensions are normal. The tricuspid valve leaflets are very mildly thickened, and a very mild jet of tricuspid regurgitation is present. The pulmonary artery and pulmonic valve are normal. No shunting lesions are visualized. No pericardial effusion or cardiac masses are seen.

ECG during echo: Sinus arrhythmia with a single VPC

LA – 33.6 mm  
LVIDd – 32.7 mm  
LVIDs – 20.5 mm  
FS – 37.2%  
RA – 20.9 mm  
LVOT – 1.62 m/s  
RVOT – 1.08 m/s

## ASSESSMENT/RECOMMENDATIONS

Degenerative mitral and tricuspid valve disease  
Ventricular premature complex (VPC)

This examination demonstrates no progression of Cooper's valvular diseases since his most recent echocardiogram. As he does not have secondary dilation of any of his cardiac chambers in today's exam, Cooper's current risk for the development of left- and/or right-sided congestive heart failure appears to be low.

A single VPC is seen in Cooper's ECG. Mild ventricular arrhythmias are well-tolerated in dogs, though careful monitoring for progression is recommended.

No change in therapy is recommended based on this exam.

A recheck ECG is recommended in 3-4 months. A recheck echocardiogram is recommended in 9-12 months.



### PATIENT

Cooper House

### SPECIES

Canine

### BREED

CKCS

### SEX

MN

### AGE

9 y

### WEIGHT

13.95 kg

### INTERPRETED BY

Keith Blass, DVM, MS,  
DACVIM (Cardiology)

### IMAGING PERFORMED BY

Dr. Brian Barnes

### HOSPITAL NAME

Westview VH

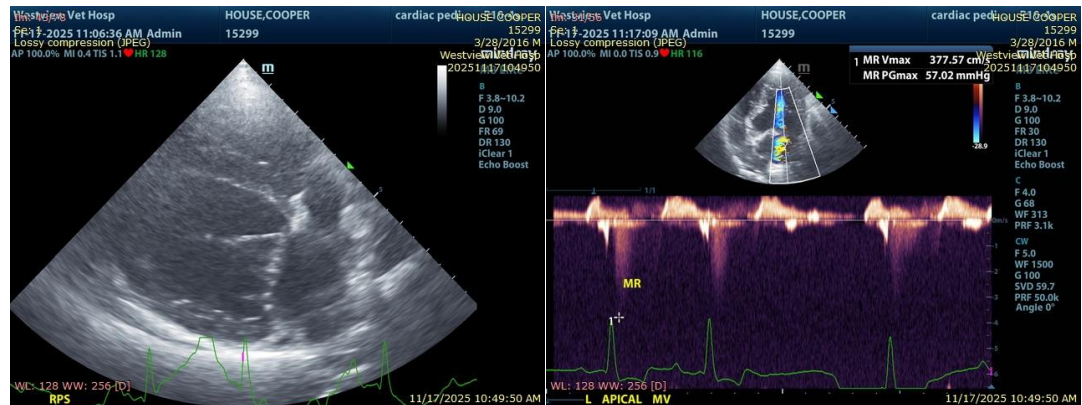
### REFERRING VET

Dr. Barnes

### INVOICE

### DATE

11/18/25



The information and recommendations provided are based on the images presented by the referring veterinarian/sonographer. No evaluation can be communicated regarding pathology that was not visible in the image/video clips provided.

Thank you for this referral. If the clinical or image interpretation does not parallel your findings or if I can be of any further assistance please contact me.

Keith Blass, DVM, MS, DACVIM (Cardiology)

[info@SonoPath.com](mailto:info@SonoPath.com)